

Ascension®

PIP Total Joint –
Dorsal Approach

SURGICAL TECHNIQUE



INTEGRA®
LIMIT UNCERTAINTY



Table of Contents

Introduction

| | |
|---|---|
| Humanitarian Device | 2 |
| Indications | 2 |
| Contraindications | 2 |
| Warnings and Precautions | 3 |
| Keys to Successful PIP Replacement..... | 4 |

Surgical Technique

| | |
|--|----|
| Preoperative Assessment | 5 |
| Step 1: Skin Incision, Capsular Opening and Exposure | 5 |
| Step 2: Medullary Canal Opening and Alignment..... | 6 |
| Step 3: First Proximal Osteotomy – Vertical Cut..... | 7 |
| Step 4: Proximal Component Broaching | 7 |
| Step 5: Second Proximal Osteotomy – Oblique Cut | 8 |
| Step 6: Middle Phalanx Exposure and Distal Surface Preparation | 9 |
| Step 7: Distal Component Broaching..... | 10 |
| Step 8: Trial Insertion – Reduction – Removal..... | 10 |
| Step 9: Implant Placement | 11 |
| Step 10: Closure..... | 12 |
| Complications | 13 |
| Salvage..... | 13 |
| Postoperative Guidelines | 14 |
| Postoperative Guidelines | 15 |
| Postoperative Guidelines | 16 |

| | |
|---|------------|
| Instrumentation | Back Cover |
| Ordering Information & Implant Dimensions | Back Cover |

Humanitarian Device

The Ascension PIP Total Joint is authorized by U.S. federal law for use in arthroplasty of the proximal interphalangeal (PIP) joint when the patient:

- has soft tissue and bone that can provide adequate stabilization and fixation under high-demand loading conditions after reconstruction; and
- needs a revision of a failed PIP prosthesis or has pain, limited motion, or joint subluxation/dislocation secondary to damage or destruction of the articular cartilage.

The effectiveness of this device for this use has not been demonstrated and as such, the use of this product requires IRB approval at your institution prior to implant placement. For more information regarding the steps required to obtain approval from your hospital's IRB board, or if you have questions concerning your present IRB approval status, please contact Integra at 877-444-1122.

Indications

The Ascension PIP Total Joint is indicated for use in arthroplasty of the proximal interphalangeal (PIP) joint when the patient:

- Has soft tissue and bone that can provide adequate stabilization and fixation under high-demand loading conditions after reconstruction; and
- Needs a revision of a failed PIP prosthesis, or has pain, limited motion, or joint subluxation/dislocation secondary to damage or destruction of the articular cartilage.

Contraindications

- Inadequate bone stock at the implantation site
- Active infection in the PIP joint
- Nonfunctioning and irreparable PIP musculotendinous system
- Physical interference with or by other prostheses during implantation or use
- Procedures requiring modification of the prosthesis
- Skin, bone, circulatory and/or neurological deficiency at the implantation site

See package insert for full prescribing information.*

Warnings and Precautions

Warnings:

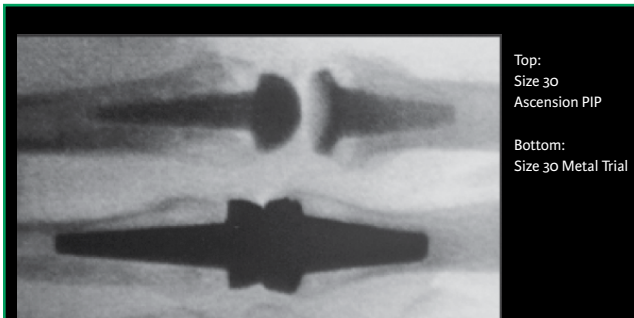
- Do not modify the PIP implant in any manner. Reshaping the implant using cutters, grinders, burs, or other means will damage the structural integrity of the device and could result in implant fracture and/or particulate debris.
- Do not match proximal and distal component sizes except as indicated in the Possible Component Size Combinations table on page 5. The wear behavior of component size combinations designated “Do Not Match” has not been evaluated, and is unknown.
- Do not grasp the PIP implant with metal instruments, or instruments with teeth, serrations, or sharp edges. Implants should be handled only with instrumentation provided by Integra. PIP implants are made of PyroCarbon, which is a ceramic-like material. Mishandling implants could cause surface damage and reduce their strength, and could result in implant fracture and/or particulate debris.
- Do not use PIP components in combination with proximal and distal components from other products. The wear behavior of PIP components against proximal and distal component from other products has not been evaluated, and could damage the structural integrity of the device and result in implant fracture and/or particulate debris.

Precautions

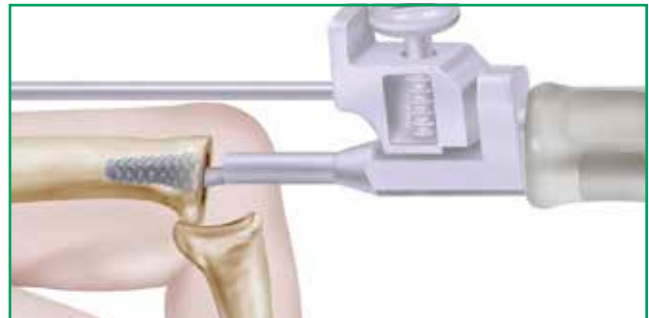- Do not use the PIP in a joint where soft tissue reconstruction cannot provide adequate stabilization. Similar to the natural joint, the PIP attains stabilization from the surrounding capsuloligamentous structures. If soft tissue reconstruction cannot provide adequate stabilization, the device may subluxate or dislocate, lateral or longitudinal deformities may occur, or minimal motion or loss of motion may occur.
- Obtain proper training prior to use. Surgeons should obtain training from a qualified instructor prior to implanting the PIP to ensure thorough understanding of the indications, implantation and removal techniques, instrumentation, and post-operative rehabilitation protocol.
- Inspect the articulating surfaces of the PIP to insure they are clean and free of all debris prior to use. Foreign debris could result in excessive wear.
- Do not resterilize this device. Resterilization could lead to mishandling and surface damage that could result in implant fracture and/or particulate debris.
- Do not reuse this device. Any implant that has been damaged, mishandled, or removed from the sterile field may have surface damage that could result in implant fracture and/or particulate debris and should be discarded. Reuse of this product may also adversely affect function of the device or result in infection or other systemic complications that may affect the patient's overall health.
- Do not use excessive impact force on the broach. Excessive impact force may cause bone fracture. Remove and reinsert broach frequently to obtain maximum cutting efficiency.
- Do not use excessive impact force to seat the proximal sizing trial. Excessive impact force could cause sizing trial fracture. The sizing trial collar should abut the osteotomy after 2 impacts. If not, re-broach to increase cavity size and/or remove additional bone to provide clearance for the saddle area.
- Do not use excessive impact force to remove the proximal sizing trial. Excessive impact force could cause sizing trial fracture. If possible, the sizing trial should be removed without the use of a hammer. If a sizing trial does fracture, and it is not possible to easily remove the remaining stem fragment, a k-wire driven into the fragment may provide sufficient purchase for removal. Then, re-broach to increase cavity size and/or remove additional bone to provide clearance for the saddle area.
- Do not use excessive impact force to seat the implant components, especially if there has been a prior sizing trial fracture. Excessive impact force could cause component fracture. The component collar should abut the osteotomy after 2 impacts. If not, re-broach to increase cavity size or remove additional bone to provide clearance for the saddle area on the proximal component.

Keys to Successful PIP Replacement

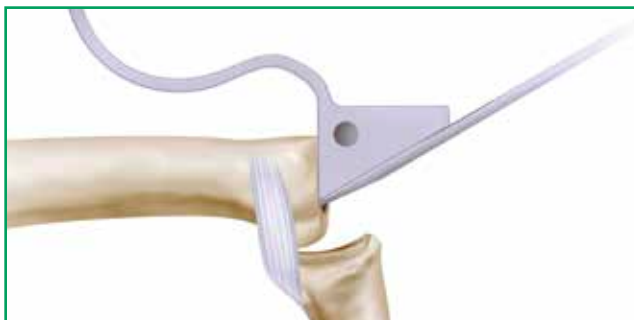Physicians should read the surgical technique in its entirety.
Pay particular attention to these items to help maximize positive surgical results.



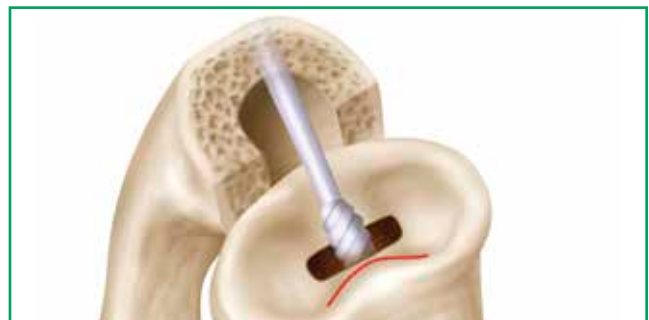The PyroCarbon material is radiolucent and is not visible on x-ray.
Tungsten material has been added for x-ray visibility.



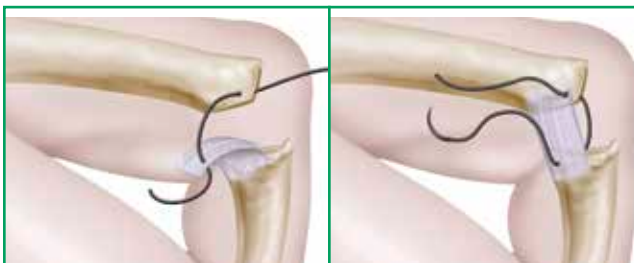
Avoid undersizing the stem. Fill the canal with the largest size broach possible to achieve a good press-fit. Confirm proper position and alignment with x-ray.



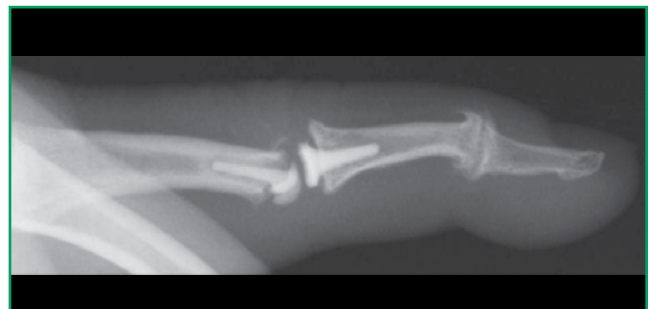During the oblique cut, make sure the cut guide is flush with the bone.
Use an osteotome to confirm that all volar bone has been removed to ensure that the implant is properly seated.



If burring within the canal is necessary, impaction grafting is highly recommended to achieve a good press-fit. Grafting is performed using morcellized graft from the proximal phalanx osteotomies.



Soft tissue balancing is paramount to a successful joint arthroplasty.
Collateral ligament stabilizing sutures may be useful at the PIP joint after insertion of the implant. This technique is most often utilized if there is excess ulnar deviation seen during the preoperative evaluation.



Avoid joint hyperextension at all costs. Minimize hyperextension by placing the PIP point in slight flexion (15-20°) immediately following surgery.

Surgical Technique

This technique has been developed in conjunction with Steven Moran, MD and Mark Ross, MB.BS, FRACS, FA(ORTH)A.



As the manufacturer of this device, Integra LifeSciences Corporation does not practice medicine and does not recommend this or any other surgical technique for use on a specific patient. The surgeon who performs any procedure is responsible for determining and using the appropriate technique in each patient.

Caution: Federal law restricts this device to sale by or on the order of a physician.

Preoperative Assessment

The patient evaluation begins with the physical exam. Painful and swollen PIP joints with limitations in motion provide the first evidence of PIP arthritis. X-ray examination of all patients should include a carefully positioned AP of the hand as well as a true isolated lateral of the involved finger(s). This will allow for careful evaluation of the joint and degree of deformity. After the patient is determined to be an acceptable candidate for surgery, discuss the postoperative finger PIP therapy regimen. The duration of postoperative surgical therapy is usually 10-12 weeks. Patient understanding and compliance with the postoperative therapy protocol is essential for a successful outcome. (See “Postoperative Guidelines” on page 14.)

The Ascension PIP Total Joint is designed for upsizing or downsizing of proximal and distal components (see table at right).

Caution

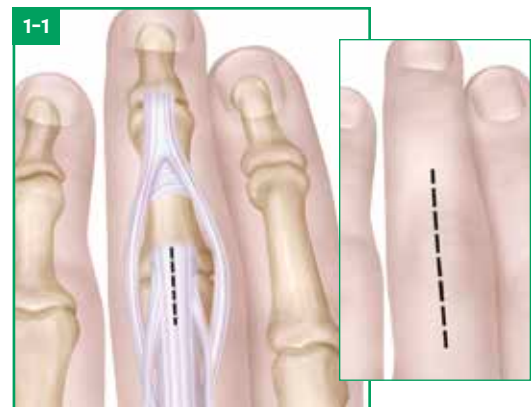
If there is evidence of insufficient bone stock, inadequate intramedullary space, marked soft tissue compromise, or ongoing active or chronic infection, arthroplasty may be contraindicated. If failure of the arthroplasty occurs, arthrodesis, fibrous arthroplasty or disarticulation may be necessary for finger salvage. All of these potential complications should be discussed with the patient in the preoperative setting.

Possible Component Size Combinations

| Size | 10P | 20P | 30P | 40P |
|------|--------------|--------------|--------------|--------------|
| 10D | ✓ | ✓ | Do Not Match | Do Not Match |
| 20D | ✓ | ✓ | ✓ | Do Not Match |
| 30D | Do Not Match | ✓ | ✓ | ✓ |
| 40D | Do Not Match | Do Not Match | ✓ | ✓ |

Step 1 • Skin Incision, Capsular Opening and Exposure

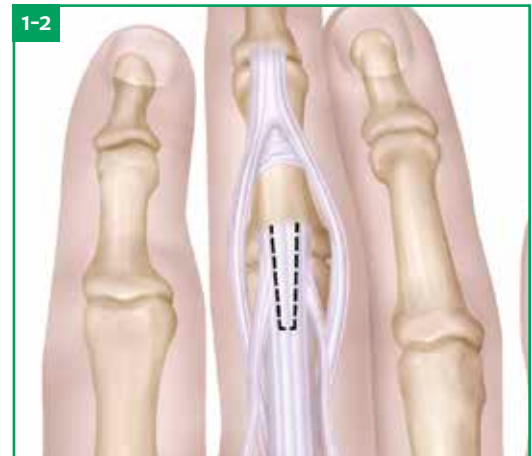
1-1 A dorsal longitudinal straight or curved skin incision, 2-3 cm in length, is made over the PIP joint. A longitudinal incision is then made through the center of the extensor tendon beginning at the middle of the proximal phalanx and ending just distal to the insertion point of the central slip of the middle phalanx. Using sharp dissection, the central slip insertion is mobilized radially and ulnarly, taking care to elevate a full thickness of the central slip insertion from the base of the middle phalanx. The middle phalanx is then flexed. This creates a radial and ulnar tendinous band which includes 1/2 of the extensor tendon and the lateral band complex. At the completion of the procedure, the tendon halves will be repaired using drill hole fixation into bone of the middle phalanx.



Step 1 • Skin Incision, Capsular Opening and Exposure (continued)

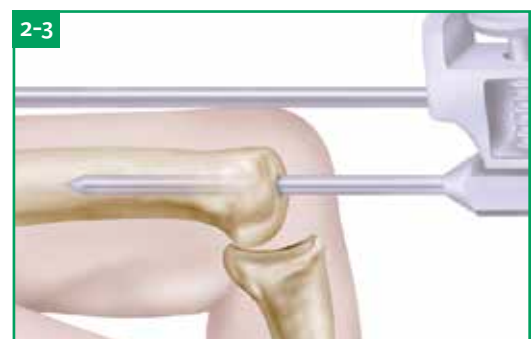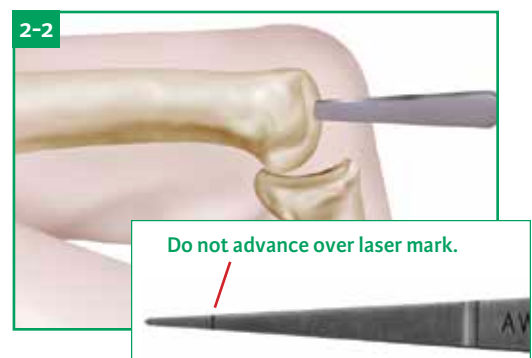
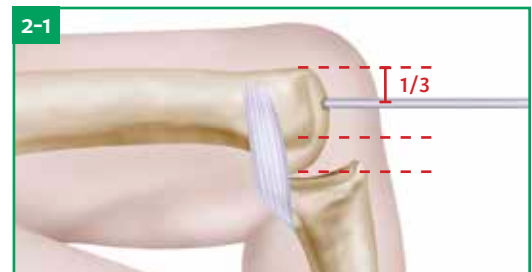
Alternative Exposure: Chamay Approach

- 1-2** Two parallel 2.0 cm incisions are made proximal to the dorsal rim along the lateral border of the central slip. The two incisions are joined with a transverse incision to form a rectangle. The extensor tendon is dissected from the underlying tissue and reflected distally to the dorsal rim of the middle phalanx.



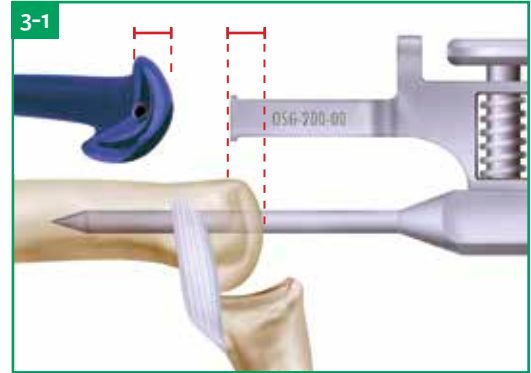
Step 2 • Medullary Canal Opening and Alignment

- 2-1** The joint is flexed to 90° and the osteophytes are removed. A 0.035" K-wire is inserted into the dorsal 1/3 of the proximal phalanx head to achieve a centralized starting point in the proximal phalanx.
- 2-2** Once the proper position is confirmed with X-ray, the hole is enlarged using the Starter Awl. The hole is made large enough for the insertion of the Alignment Awl into the medullary canal. Do not advance the Starter Awl over the laser mark, as this will cause the Alignment Awl to shift during the vertical osteotomy.
- 2-3** The Alignment Guide is attached to the Alignment Awl and inserted into the proximal phalanx. The Alignment Awl should be positioned parallel to the dorsal surface of the proximal phalanx and in line with the long axis of the bone. The centralized position can be confirmed with X-ray in both AP and lateral views.



Step 3 • First Proximal Osteotomy – Vertical Cut

3-1 While maintaining Alignment Awl position, the Alignment Guide is removed and replaced with the Vertical Cut Guide. The Vertical Cut Guide is placed 0.5-1.0 mm distal to the proximal attachments of the collateral ligaments. The proper guide position can be confirmed by placing the saw blade (safe mode) onto the Cut Guide and checking the osteotomy position. Viewing the templated size Proximal Trial laterally can serve as an additional visual guide for the osteotomy. Using a micro sagittal saw, the articular surface of the proximal phalanx is partially removed. Once the starting cut has been made, the Alignment Awl is removed from the medullary canal and the cut is completed.



Surgical Pearl

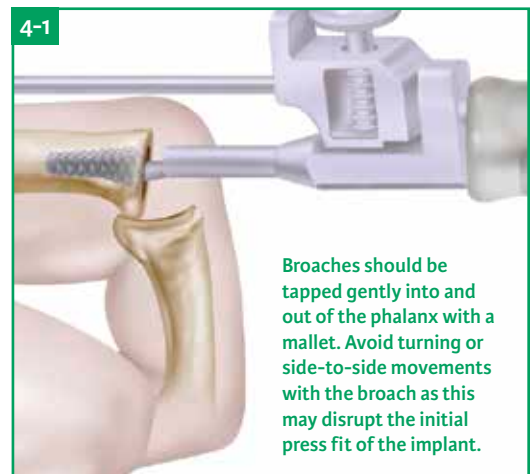
Save offcuts for impaction grafting.

Step 4 • Proximal Component Broaching

4-1 Following the vertical cut, the proximal phalanx is broached. The goal is to fill the medullary canal with the largest implant stem possible while maintaining centralized alignment within the canal. Be sure to evaluate both the AP and Lateral views on the X-ray before proceeding to the next Broach as this will determine if you can increase your Broach size and ensure proper positioning.

In some cases, the proximal phalanx bone stock may be hard and sclerotic. If the Broach cannot be fully inserted, additional bone stock must be removed. To aid in this process, a side-cutting burr can be used to open the entry of the proximal phalanx in order to begin broaching. It is important to minimize burring within the canal as this will disrupt the press fit of the implant, and may damage the endosteal bone. Overheating the bone should be avoided at all costs. It is strongly suggested to use irrigation while utilizing powered burrs. If burring within the canal is necessary, impaction grafting is highly recommended. (See page 11.)

With the Alignment Guide attached, begin with the smallest size Broach and insert it halfway into the medullary canal. Proper positioning is confirmed with lateral and AP X-rays. If you notice any mal-alignment, remove the broach and correct positioning with a side-cutting burr. Re-insert the Broach and confirm position with X-ray. The Broach may now be fully seated. Continue upsizing the Broach size until you have filled the medullary canal or are limited in one view (AP/Lateral). Most often, you will be limited in the lateral view. The final Broach should be seated flush, or slightly recessed, with the vertical edge of the osteotomy. Incomplete or partial insertion of the Broach should be corrected prior to Trial insertion.



Surgical Pearl

It should be noted that the proximal component may only be one size larger than the final distal component. Preoperative templating can be helpful to estimate component sizing, paying particular attention to the lateral view.

Possible Component Size Combinations

| Size | 10P | 20P | 30P | 40P |
|------|--------------|--------------|--------------|--------------|
| 10D | ✓ | ✓ | Do Not Match | Do Not Match |
| 20D | ✓ | ✓ | ✓ | Do Not Match |
| 30D | Do Not Match | ✓ | ✓ | ✓ |
| 40D | Do Not Match | Do Not Match | ✓ | ✓ |

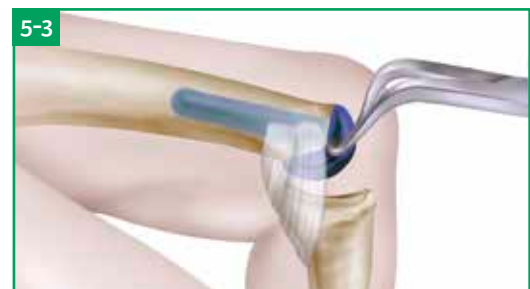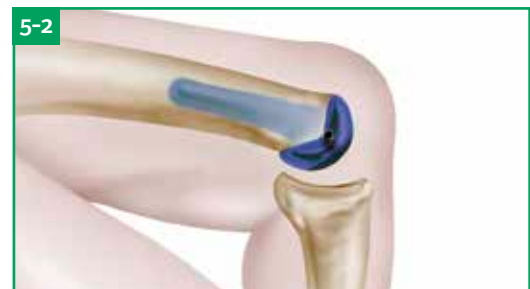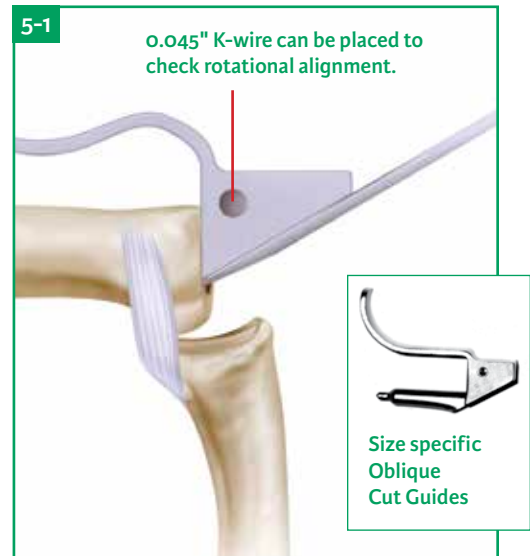
Step 5 • Second Proximal Osteotomy – Oblique Cut

5-1 The Oblique Cut Guide is placed into the medullary canal of the proximal phalanx. The size of the guide should be the same size as the final Broach used. The Oblique Cut Guide must be fully inserted into the broached medullary canal, this can be confirmed with light tapping with a mallet. Full insertion is achieved when the seating plane on the guide contacts the vertical osteotomy. Incomplete or partial insertion exists if there is a gap between the seating plane and the vertical osteotomy. It is important to check rotational positioning of the Oblique Cut Guide, as this will determine the rotation of the prosthesis, which can be confirmed by inserting a K-wire into the hole on the Oblique Cut Guide and evaluating position.

Using a sagittal saw, place the blade flush with the cutting guide and perform the entire bony cut. It is imperative that the proper angle is maintained while making the osteotomy, so ensure your saw blade is flush with the Oblique Cut Guide. To ensure all bone fragments are removed, an osteotome can be passed down the Oblique Cut Guide along the osteotomy plane. If bone fragments are found, additional shaving passes with a saw or osteotome will be required to ensure adequate bone removal and adequate implant seating.

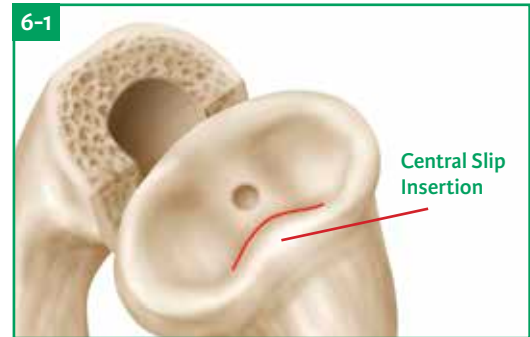
5-2 At this time the appropriately sized proximal Trial is inserted and examined. The Trial surfaces should seat flush against both the vertical and oblique osteotomy surfaces. The Trial may be tapped lightly into better contact with the proximal phalanx, but if the Trial is not seating completely flush, re-broach to increase cavity size and/or remove additional bone to provide clearance for the Trial. Evaluate the joint position with lateral and AP X-rays and by taking the finger through ROM.

5-3 To remove the Trial, insert the Trial Extractor tongs into the lateral sides of the Trial between the collar of the Trial and the osteotomies.

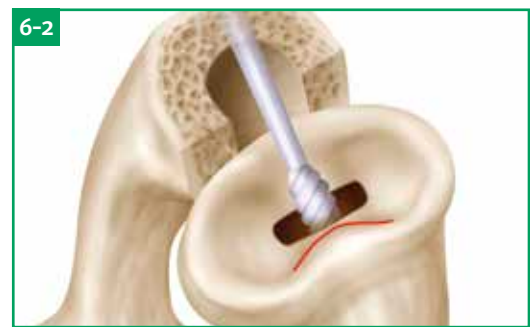

Step 6 • Middle Phalanx Exposure and Distal Surface Preparation

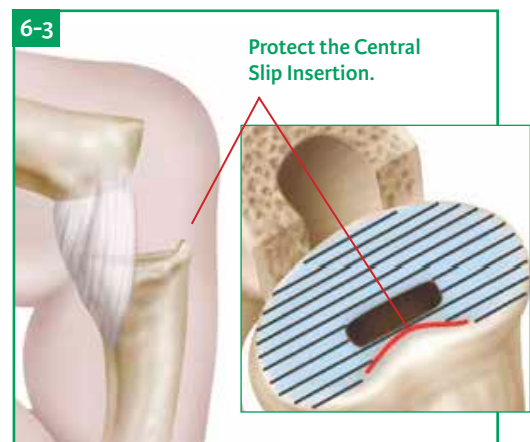
6-1 After completion of the proximal side, the joint is hyper-flexed to expose the articular surface of the middle phalanx. Osteophytes are removed and a 0.035" K-wire is inserted into the dorsal 1/3 of the base of the middle phalanx, and the position is confirmed with X-ray. It is undesirable to position the distal component too volar as this may disrupt the joint mechanics.



6-2 After confirmation, the hole is enlarged with the Starter Awl and further enlarged with a side-cutting burr to create an opening to accept the distal Broach. Irrigation is recommended while utilizing powered burrs.



6-3 Using a small end cutting burr, remove the articular surface of the middle phalanx base taking care to preserve as much of the central slip insertion as possible. The Distal Sizing Template can be used to determine if the head will seat uniformly on the smoothed surface, or if additional bone removal is required. It also shows how much bone can be maintained for the central slip insertion.

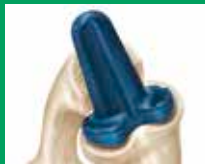

Distal Sizing Template



Surgical Pearl

You can also confirm proper distal surface preparation by holding the trial implant upside down onto the middle phalanx.

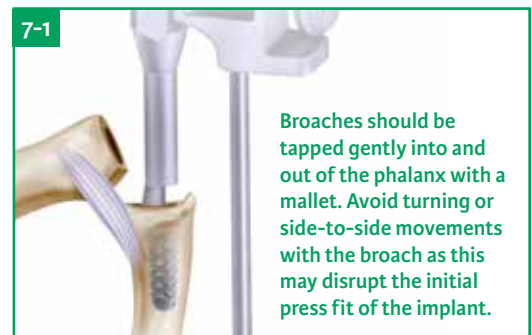


Step 7 • Distal Component Broaching

After an entry way is made to allow insertion of the Size 10 Distal Broach the canal is broached. The goal is to insert the largest implant possible while maintaining a centralized alignment within the canal. The Distal Broach size can be the same size, one size smaller, or one size larger than the size selected for the proximal component. (See “Possible Size Combinations” on page 5.)

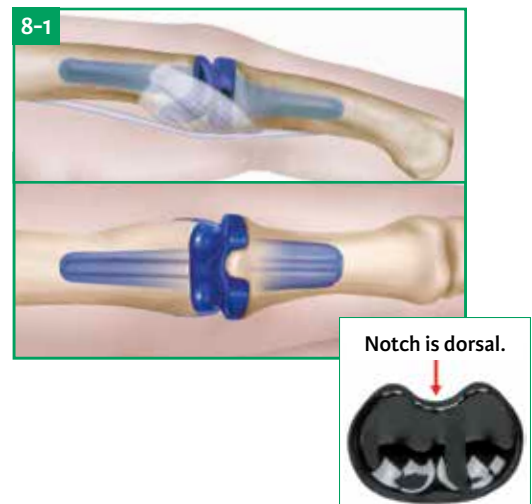
In some cases, middle phalanx bone stock may be hard and sclerotic. If the Broach cannot be fully inserted, additional bone stock must be removed; to aid in this process a side-cutting burr can be used to open the entry of middle phalanx in order to begin broaching. It is important to minimize burring within the canal as this will disrupt the press fit of the implant, and may damage the endosteal bone. Overheating the bone is to be avoided at all costs. It is strongly suggested to use irrigation while utilizing powered burrs. If burring within the canal is necessary, impaction grafting is highly recommended. (See page 11.)

- 7-1** Begin with the smallest size Distal Broach with the Alignment Guide attached and insert it halfway into the medullary canal. Proper positioning is confirmed with lateral and AP X-rays. If you notice any malalignment, remove the Broach and correct positioning with a side-cutting burr, re-insert the Broach and confirm position with X-ray. Once proper position is confirmed the canal may be sequentially enlarged with the broaches until the final broach rests flush to 0.5 mm deeper than the osteotomy level. Incomplete or partial insertion of the Broach should be corrected before the Trial is inserted.

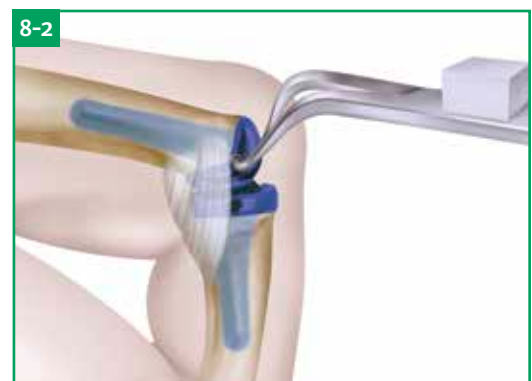

Step 8 • Trial Insertion – Reduction – Removal

- 8-1** The joint is then flexed and the appropriately sized Distal Trial is inserted. To ensure correct axial rotation, verify the intercondylar notch is dorsal. Use the Distal Impactor to lightly impact the Trial to ensure a press fit. The collar should abut the cut surface after 2 impacts. The Proximal Trial should be seated with finger pressure first and checked before impaction to ensure complete seating against osteotomy angles. To ensure complete seating, hyper-flex the PIP and examine the alignment of the osteotomies against the component from the lateral view on both sides. There should be both dorsal and volar collar contact. If there is incomplete seating, a correction is required – examine both osteotomies and ensure the vertical cut is perpendicular to the axis of the bone, and that there are no volar bone fragments that may be impeding the trial from seating. The finger should extend and flex passively with ease but with minimal lateral play or laxity with traction.



- 8-2** Use the Trial Extractor to remove Trials (proximal first) by inserting extractor tongs into the lateral sides of the Trial, between the collar of the Trial and the osteotomy.



Step 8 • Trial Insertion – Reduction – Removal (continued)

Surgical Pearls

If you have over broached or utilized burrs in the intramedullary canal:

This may occur inadvertently during attempts at placing larger implants or in patients with very sclerotic bone. In such cases, cancellous allograft may be impaction grafted into the intramedullary canal using the Trial. Grafting is performed using morcellized graft from the proximal phalanx osteotomies. Grafting may be continued until the final Broach or Trial size fits snugly against the osteotomy edge.

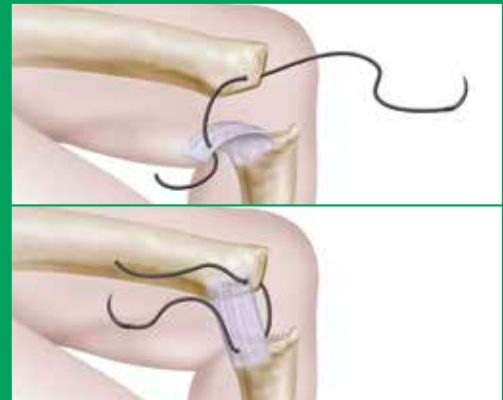
If a lax joint is encountered:

Ensure you have selected the largest size implant that can fit into the medullary canals. Occasionally a larger implant may be placed either proximally or distally by enlarging the intramedullary canal with a burr. If stability is not obtained with a larger implant, closely examine the collateral ligament insertion sites; these may have been inadvertently damaged during the osteotomy process. If collateral ligament stability has been compromised, a collateral ligament stitch will be required to re-establish lateral stability.

Collateral ligament stabilizing sutures:

Stabilizing sutures may be useful at the PIP joint when there is radial or ulnar laxity or a tendency for hyperextension after insertion of the implant trials. This technique is most often utilized if there is excess ulnar deviation seen during preoperative evaluation. Adequate soft tissue is usually found at the mid-portion of the proximal phalanx in the vicinity of the accessory collateral ligament. Distally, the volar plate and insertion areas of the collateral ligament are usually sufficient to support a strong suture. If adequate soft tissue purchase is not possible with a standard suture, a drill hole prepared with a .045" K-wire can be utilized to pass the suture through bone for fixation. The drill holes may be created at the lateral margins of both the proximal and middle phalanges.

The suture should be inserted with the implant in place if bone fixation is not required. A strong absorbable (2-0 or 0) or non absorbable (2-0) suture is used on a larger needle. The suture is passed in a horizontal mattress fashion volarly through the proximal phalanx soft tissues and then through the middle phalanx soft tissues volarly, with the joint reduced. The sutures may be placed on one or both sides of the joint depending on the clinical situation. The implant is then extended until it reaches 15° of extension lag. The sutures are tied snugly, first on one side and then the other side of the joint. Alternatively, if a transosseous suture is utilized, they should be placed before the insertion of the prosthesis. The volar placement of the suture will prevent hyperextension. If hyperextension is seen following suture placement, sutures should be re-directed to a more volar position.

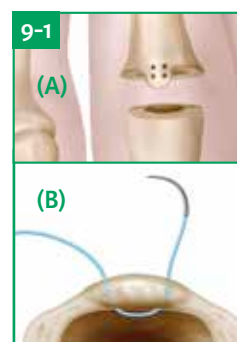


If a tight joint is encountered:

Increasing the depth of the proximal osteotomies can increase the joint space to improve extension or relieve tension. Remove bone in small increments to avoid laxity or instability. Rebroach the medullary canal, examine osteotomies and reinsert the trials. Reduce the joint and assess stability, joint laxity, and range of motion.

Step 9 • Implant Placement

- 9-1** After successful Trial insertion and reduction, a fine K-wire (0.035") may be utilized to drill two sets of holes in the central dorsal bony ridge through which strong sutures may be passed for the reattachment of the middle slip. The sutures are placed before the Ascension PIP implants are inserted.



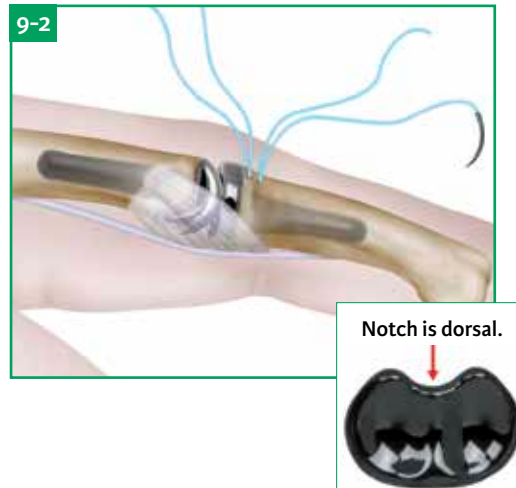
(A) If using only one set of sutures, place them proximally. This will help to ensure the extensor tendon is repaired in an anatomic position.

(B) Suture is passed dorsally into the medullary canal and back out the transverse hole.

Step 9 • Implant Placement (continued)

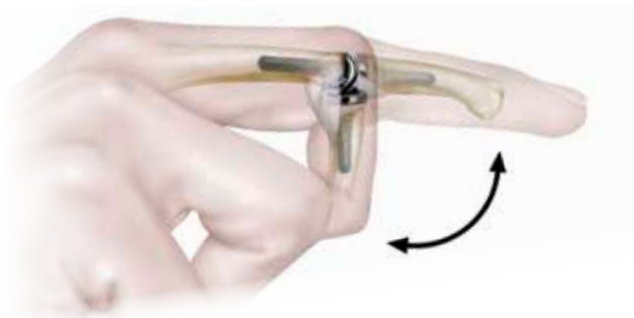
9-2 The appropriately sized distal and proximal sterile components are opened. Insert the distal component first. To assure correct axial rotation, verify the intercondylar notch is dorsal. Use the Distal Impactor, in line with the implant, to apply firm but gentle force to secure a good press fit. Flex the joint to avoid impingement on the distal component when inserting the proximal component. Insert the proximal component with finger pressure. Use the Proximal Impactor with firm but gentle force to ensure a good press fit. Do not use excessive force to seat the implant. The collar should abut the surface after minimal impacts. If not, re-broach to increase cavity size or remove additional bone.

Always take final intraoperative radiographs of both the AP and lateral views. Examine these radiographs to confirm that implants have been placed centrally within the intramedullary canal.



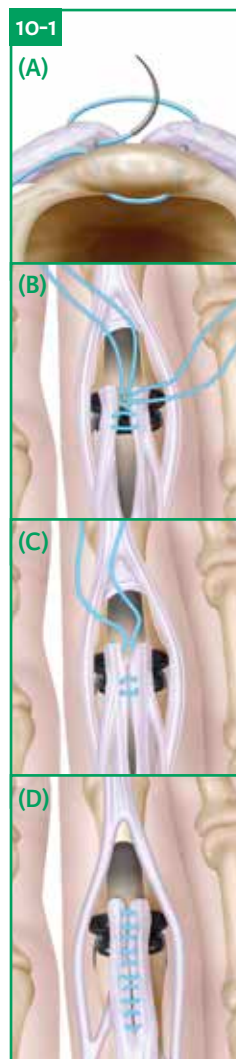
Step 10 • Closure

10-1 The middle slip reconstruction is achieved by utilizing the sutures that have been passed through the drill holes in the middle phalanx to grasp both the radial and ulnar aspects of the extensor tendon flaps created at the beginning of the surgical procedure. The remaining proximal tenotomy can then be repaired with a series of interrupted 4.0 non-absorbable sutures. At the conclusion of the middle slip reconstruction, the repair should be strong enough to confidently flex down to 90° on the table (see figure below). This will facilitate postoperative rehabilitation utilizing an accelerated short arc active range of motion program.



The skin is closed with nonabsorbable sutures, and a padded dressing with a plaster splint is applied with the finger in slight flexion at PIP and DIP (10-15°), with 20-30° of flexion at the MCP.

It should be emphasized that full PIP extension should not be the goal of surgery. Often full extension may lead to PIP joint hyperextension and may result in complications. Our preference is to end up with a fixed flexion deformity at the PIP joint of between 5-10°. This provides excellent function and minimizes the risks associated with PIP hyperextension. Therapy directed at preventing PIP hyperextension is discussed on page 14.



(A) Suture passage is performed prior to implant insertion. Sutures are tied after implantation.

(B) The proximal transosseous suture is passed from the deep surface of the tendon to the superficial aspect and back again twice. Suture is tied beneath the tendon creating a tight closure.

(C) The distal transosseous suture is passed similarly through remaining tendon halves, creating a tight secure closure of the extensor tendon into its insertion point in the base of the middle phalanx. Care should be taken not to incorporate the lateral bands with the suture as this will limit DIP ROM.

(D) The remaining proximal tenotomy can then be repaired with a series of interrupted 4.0 non-absorbable sutures.

Complications

The most common complications following PIP arthroplasty are:

- 1. Joint Instability** – can result in dislocation, hyperextension, or radial or ulnar deviation. The causes of joint instability are:
 - A) Improper placement of the implant** – most frequently seen in the proximal component where the stem is placed dorsally or palmarly, leading to increased eccentric loading of the joint surface. In such cases the implant can be reinserted after impaction grafting and re-broaching to ensure the implant is now seated within the center of the intramedullary canal. Joint stability may also be improved by increasing the implant size of either the proximal or distal implant. X-rays are advised to confirm that the patient's anatomy can accept a larger size implant: impaction grafting is also suggested. The one size mismatch between proximal and distal must be respected if considering a change in implant size.
 - B) Inadequate soft tissue stabilization** – inadequate soft tissue can also frequently lead to postoperative instability or frank dislocation of the joint. The cause of the soft tissue deficiency can include inadvertent injury to the collateral ligaments during the surgical procedure, inflammatory arthritis and attritional degeneration. In all cases, soft tissue stabilization sutures should be added to improve stability. Collateral ligament sutures, in conjunction with extensor tendon drill holes, help establish joint stability during the rehabilitation process. Scarring and capsular healing allow for re-establishment of long-term joint stability.
 - C) Loss of bony support** – can occur if a fracture occurs in the postoperative period or intraoperatively. In such cases the bone can be reinforced with cerclage wires or sutures. Alternatively, a silicone implant may be used temporarily, until the bone heals, allowing the re-insertion of an Ascension PIP implant.
- 2. PIP Stiffness** – can result following PIP arthroplasty and is usually rectified with physical therapy. Occasionally, flexor or extensor tendon tenolysis and partial collateral ligament release are necessary to restore complete joint flexion.
- 3. Joint Hyperextension** – at the PIP joint can be seen following improper splinting or placement of the implants. A flexed alignment of the proximal component or extensive volar placement of the distal component, increases the lever arm of the middle slip, thereby predisposing the joint to hyperextension. In such cases, a hyperextension deformity can be seen early within the postoperative course. Such implants will often “squeak” during flexion. Correction of this deformity can be performed by placing the patient into a dorsal blocking splint, holding the finger in 15-20° of flexion. This splint is maintained for 4-8 weeks. If splinting does not resolve the problem, re-positioning of the implant may be necessary. For extreme cases, a superficialis tenodesis may be necessary to hold the PIP joint in mild flexion.

Salvage

Occasionally situations will necessitate removal of the implant. These occurrences are rare and have mainly been limited to persistent joint instability and joint infection. In cases of persistent instability, not amenable to arthroplasty revision, the implant can be removed and exchanged for a constrained silicone implant. Alternatively, the patient can undergo a joint fusion. Joint fusion may be performed with any number of surgical techniques. Bone grafting is often required to accelerate the healing process, as medullary bone has been removed during the arthroplasty process.

Postoperative Guidelines

Please see the full Ascension PIP Postoperative Therapy for the expanded postoperative therapy guidelines. As described by Wilma Walsh of Extend Rehabilitation and Associate Professor Mark Ross of the Brisbane Hand and Upperlimb Clinic, Brisbane, Australia. The following protocol was designed as a guideline for treating patients with degenerative and post-traumatic arthritis, who have a good central slip and ligament integrity. **Patients with rheumatoid arthritis require individual assessment of preoperative deformity and periarticular soft tissue quality, and may need up to three weeks of immobilization to provide for soft tissue stabilization prior to initiation of therapy.**

Precautions

Variations depend upon the integrity of the central slip/fibro-osseous insertion. Hyperextension of the PIP must be AVOIDED, as this may lead to complications. Since even neutral extension may drift toward hyperextension over time, a long term mild fixed flexion deformity (5-10°) is preferred to help prevent hyperextension. In addition, apparent neutral extension clinically may represent hyperextension at the articulation due to the variability of soft tissues.

Philosophy of Rehabilitation Strategy

This rehabilitation strategy aims to maximize return of range of motion while protecting the integrity of the middle slip. It is a variation of the short arc active range of motion (SAM) protocol as described by Roslyn Evans originally for rehabilitation of middle slip injuries. This protocol is accelerated as patients have the usual resting splint, however, their flexion range is allowed to progress more rapidly as long as they do not develop any extensor lag and hyperextension is avoided at all costs.

The speed at which flexion is pursued is influenced by the surgeon's assessment of the quality of the middle slip reattachment. A strong transosseous reinsertion of the middle slip, under anatomic tension, is suggested to facilitate pursuit of this early active ROM protocol.

Every PIP patient will have program adjustments and individual consideration must be given according to surgeon directive. To assist the therapist, it is helpful to communicate the integrity of the soft tissue structures.

Initial Assessment

- Preoperative ROM/function
- Pre- & postoperative pain levels
- Reason for surgery
- Integrity of soft tissue structures (noted by the surgeon intraoperatively), especially central slip and collateral ligaments
- Type/strength of repair
- Type/strength of middle slip repair/reattachment

1-2 Weeks Postoperative Care

Wound / Edema Control

- Wound care – debulk dressings
- Compression/ Elevation

Splints

Resting splint

- Dorsal static PIP extension splint
- Blocking PIP in 15-20° flexion
- DIP may be included, if susceptible to lag
- Thin LTT suggested
- Consider any lateral instability and extend at sides to give appropriate support.

Exercise splint as per the active short arc motion (SAM) protocol – only required if central slip integrity is compromised or lag is evident.

Postoperative Guidelines

Exercises

For patients with good central slip integrity:

Accelerated SAM Protocol

- Perform exercises in dorsal resting splint with distal strap removed
- Active PIP flexion – amount of flexion is titrated against the maintenance of active extension, i.e. extension lag
- If minimal lag, aim for 70-80° of flexion by the end of week 2
- Blocked DIP flexion (Active)
- Gentle composite flexion (active)
- Active extension to dorsal extension block splint
- “Place and hold” active extension if lag
- Frequency: 5-10 repetitions, 5X daily

For those with compromised central slip integrity:

Standard SAM Protocol

- Blocked DIP flexion (Active)
- Active PIP flexion to exercise splint (30-45°)

Other

- Avoid deviation/rotation
- No strong gripping, pinching, lifting, etc.
- Light ADL's

3-4 Weeks Postoperative Care

Wound / Edema Control

- Compression as necessary – may change to Lycra (take care to avoid hyperextension)
- Scar massage

Splint

- Resting splint as previously described
- Exercise splint if using Standard SAM protocol – increase PIP flexion to 45-60°

Exercises

For patients with good central slip integrity:

Accelerated SAM

- If difficulty achieving flexion, include active hook (DIP and PIP flexion with MCP in extension; should have full DIP flexion)
- At four weeks, aim for -10° extension (10° FFD)
- Avoid hyperextension
- Intrinsic extension (blocked PIP extension to -10°)

For patients with compromised central slip integrity:

Standard SAM

- Increase to 45-60° PIP flexion
- Allow extension to -10° at 4 weeks; Avoid hyperextension

Postoperative Guidelines

Other

- Avoid medial / lateral deviation or rotation
- No strong gripping, pinching, lifting, etc.
- Light ADL's

5-6 Weeks Postoperative Care

Wound / Edema Control – Compression as needed

Splint

- Continue resting splint – if lag, ensure DIP is included; intermittent wear during day
- Cease exercise splints
- May use buddy taping, if flexion is poor or there are alignment issues

Exercises

Accelerated SAM or modified SAM

- Active flexion – no limits
- If stiff, isolated passive DIP; if lag, place/hold extension+++
- Continue to aim for -10° (at PIP)

Other – Encourage use in ADL

7-8 Weeks Postoperative Care

Wound / Edema Control – Compression as necessary

Splint – Cease splinting if no extension lag is present

Exercises

Accelerated SAM or modified SAM

- Active flexion – no limits
- Aim for full flexion
- If stiff, isolated passive DIP; if lag, place/hold extension+++
- Continue to aim for -10° (at PIP)
- May commence gentle passive assist, if no lag exists

8-12 Weeks Postoperative Care

Wound / Edema Control – Compression as necessary

Splint – Cease splinting if no extension lag is present

Exercises – If lag exists, commence gentle resisted extension

Other – Avoid isolated pinch, especially for Index

Implant Removal

In the event that it becomes necessary to remove an Ascension® PIP component or implant, the following should be considered.

First, it is recommended that extracted components not be reused due to potential damage to the component created during the removal process. Second, use of instruments not manufactured by Integra Lifesciences to extract the Ascension® PIP is not recommended. Metallic instruments normally used for grasping objects, such as rongeurs or hemostats, or instruments with serrations, teeth or sharp edges can fracture the implant, making it more difficult to remove any remaining implant stem, and should not be used.

To aid in component removal, the Trial Extractor is provided in the Instrument Tray. The proximal component must be removed first. With the joint in hyper-flexion the wedged ends of the Trial Extractor should be placed under the collar of the component and gently tapped with a small mallet. If this is not successful or the Trial Extractor cannot gain purchase on the component, try to extract the device with a blunt ended osteotome or periosteal elevator.

If this approach is not successful, consider the following options:

1. Using a sizing trial, measure the stem length of the implant on the dorsal surface of the metacarpal and drill a small (2mm) hole in the dorsal surface of the metacarpal bone just proximal to the tip of the stem. Use a k-wire or 2mm instrument to push the implant loose from the medullary canal; or
2. Make a small axial cut dorsally in the metacarpal or proximal phalanx cortex adjacent to the subarticular collar of the implant. This will allow the cortex to open like a "book" to access the implant after which gentle impaction on the stem of the implant may be used to remove the component from the medullary canal. If another implant is to be inserted, a circumferential suture may be placed around the cortex to close the gap that was created.


If the component head fractures from the stem during the removal attempt, and the stem cannot be easily extracted with a grasping instrument, consider the following options:

1. It may be possible to place a k-wire parallel to the component stem using a powered wire driver. This can be attempted in several locations to loosen the implant stem. Then, use a rongeur or Kelley clamp to grasp the stem to remove it; or
2. Use a burr to remove a portion of or all of the remaining stem. The use of a burr in this manner will result in debris in the wound, and irrigation and debridement are recommended to eliminate the foreign particles.



Instrumentation

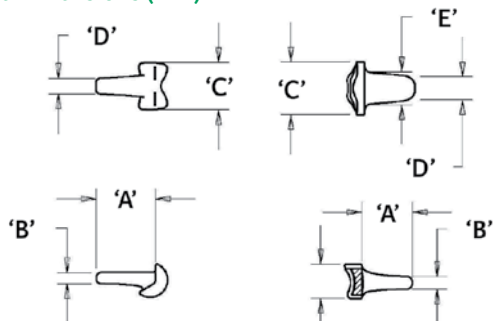
1. Starter Awl
2. Alignment Awl
3. Alignment Guide
4. Vertical Cut Guide
5. Proximal Oblique Cut Guides
6. Distal Sizing Template
7. Distal Broaches
8. Proximal Broaches
9. Trials
10. Distal Impactor
11. Proximal Impactor
12. Trial Extractor



Implants

| Catalog Number | Description |
|----------------|---------------------------------|
| PIP-200-10D-WW | PIP Distal Component, Size 10 |
| PIP-200-10P-WW | PIP Proximal Component, Size 10 |
| PIP-200-20D-WW | PIP Distal Component, Size 20 |
| PIP-200-20P-WW | PIP Proximal Component, Size 20 |
| PIP-200-30D-WW | PIP Distal Component, Size 30 |
| PIP-200-30P-WW | PIP Proximal Component, Size 30 |
| PIP-200-40D-WW | PIP Distal Component, Size 40 |
| PIP-200-40P-WW | PIP Proximal Component, Size 40 |

Implant Dimensions (mm)



| SIZE | (A) STEM LENGTH | (B) STEM HEIGHT | (C) HEAD WIDTH | (D) STEM WIDTH | (E) STEM WIDTH | (F) HEAD HEIGHT |
|------|-----------------|-----------------|----------------|----------------|----------------|-----------------|
| 10P | 9.5 | 1.8 | 7.5 | 2.5 | N/A | N/A |
| 10D | 8.1 | 2.0 | 8.6 | 3.8 | 5.4 | 5.5 |
| 20P | 11.7 | 2.3 | 8.6 | 2.7 | N/A | N/A |
| 20D | 9.7 | 2.3 | 9.7 | 3.9 | 5.8 | 6.4 |
| 30P | 13.8 | 2.8 | 9.7 | 2.8 | N/A | N/A |
| 30D | 11.4 | 2.6 | 10.7 | 4.1 | 6.2 | 7.0 |
| 40P | 16.0 | 3.3 | 10.8 | 3.2 | N/A | N/A |
| 40D | 13.2 | 2.8 | 11.7 | 4.3 | 6.3 | 8.0 |

Instruments

| Catalog Number | Description |
|----------------|-------------------------------------|
| ALG-100-00 | Alignment Guide |
| AWL-100-01 | Starter Awl |
| AWL-200-00 | Alignment Awl |
| BRH-200-10D | Distal Broach, Size 10 |
| BRH-200-10P | Proximal Broach, Size 10 |
| BRH-200-20D | Distal Broach, Size 20 |
| BRH-200-20P | Proximal Broach, Size 20 |
| BRH-200-30D | Distal Broach, Size 30 |
| BRH-200-30P | Proximal Broach, Size 30 |
| BRH-200-40D | Distal Broach, Size 40 |
| BRH-200-40P | Proximal Broach, Size 40 |
| EXT-200-00 | PIP Trial Extractor |
| IMP-200-00D | PIP Distal Impactor |
| IMP-200-00P | PIP Proximal Impactor |
| OSG-200-00 | Vertical Cut Guide |
| OSG-200-10P | Proximal Oblique Cut Guide, Size 10 |
| OSG-200-20P | Proximal Oblique Cut Guide, Size 20 |
| OSG-200-30P | Proximal Oblique Cut Guide, Size 30 |
| OSG-200-40P | Proximal Oblique Cut Guide, Size 40 |
| TMP-200-01 | Distal Sizing Template |
| TRL-202-10D | Ti Distal Trial, Size 10 |
| TRL-202-10P | Ti Proximal Trial, Size 10 |
| TRL-202-20D | Ti Distal Trial, Size 20 |
| TRL-202-20P | Ti Proximal Trial, Size 20 |
| TRL-202-30D | Ti Distal Trial, Size 30 |
| TRL-202-30P | Ti Proximal Trial, Size 30 |
| TRL-202-40D | Ti Distal Trial, Size 40 |
| TRL-202-40P | Ti Proximal Trial, Size 40 |

Availability of these products might vary from a given country or region to another, as a result of specific local regulatory approval or clearance requirements for sale in such country or region.

- Non contractual document. The manufacturer reserves the right, without prior notice, to modify the products in order to improve their quality.
- Warning: Applicable laws restrict these products to sale by or on the order of a physician.
- Consult product labels and inserts for any indication, contraindications, hazards, warnings, precautions, and instructions for use.

For more information or to place an order, please contact:

United States, Canada, Asia, Pacific, Latin America

USA 800-654-2873 ▪ 888-980-7742 fax

International +1 609-936-5400 ▪ +1 609-750-4259 fax

integralife.com/contact

Manufacturer:



Ascension Orthopedics, Inc.

11101 Metric Blvd

Austin, TX 78758 ▪ USA